

MAINTENANCE OF MARGINAL BONE SUPPORT AT OSSEOSPEED™ PROFILE IMPLANTS

201

Noelken R¹, Donati M², Fiorellini J³, Gellrich N-C⁴, Parker W⁵, Berglundh T⁶

¹ Private Practice, Lindau / Lake Constance & University of Mainz, Germany, ² Private Practice, Perugia, Italy, ³ University of Pennsylvania, USA, ⁴ University of Hannover, Germany, ⁵ Nova Southeastern University, Fort Lauderdale, USA, ⁶ University of Gothenburg, Sweden

Topic: Implant therapy outcomes, surgical aspects

Background and Aim

In situations where the alveolar crest anatomy is sloped in a lingual to buccal direction, the placement of a regular implant is not optimal. A dental implant with a sloped marginal contour, OsseoSpeed™ Profile (Astra Tech AB, Mölndal, Sweden), has been developed to optimize implant placement in such situations. The aim of the study was to evaluate the maintenance of lingual/palatal and buccal marginal bone support after 16 weeks when placing OsseoSpeed™ Profile implants in healed ridge sites, where the alveolar crest anatomy was sloped in a lingual to buccal direction. The follow-up period will continue for a total of three years.

Methods and Materials

In this prospective, open, multicenter study, 60 patients between 18 and 75 years of age with a need for a single tooth replacement in any location were included. The recipient sites presented with a lingual-buccal bone height difference of 2.0-5.0 mm and a history of edentulism of at least 3 months. Main exclusion criteria were smoking more than 10 cigarettes per day and a health status that would not allow implant placement.

OsseoSpeed™ Profile implants (Astra Tech AB, Mölndal, Sweden) in diameters 4.5, 5.0 and 5.0S with lengths 9-15 mm were used in the study. A one-stage surgical protocol was utilized, and healing abutments were used during the 16 weeks healing period. Lingual and buccal bone level alterations were assessed using a periodontal probe at the time of implant placement and the surgical re-entry visit 16 weeks after implant placement.

Results

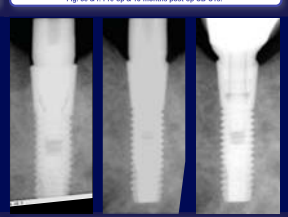
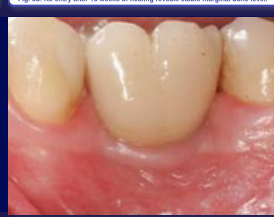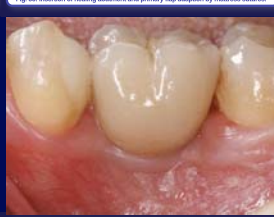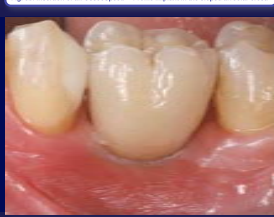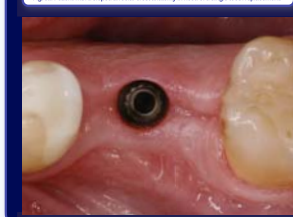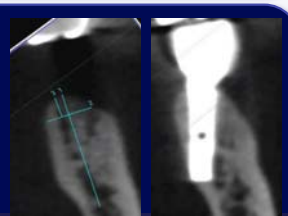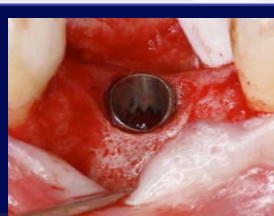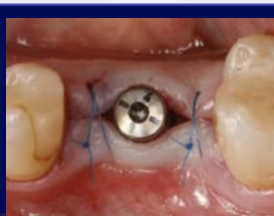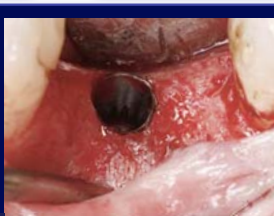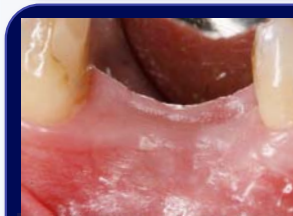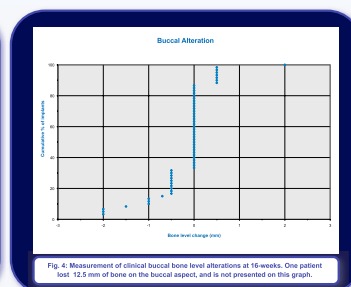
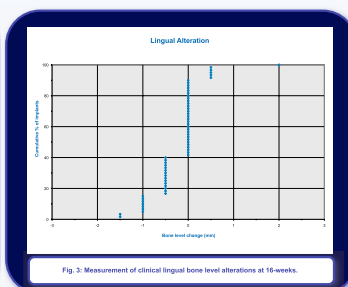
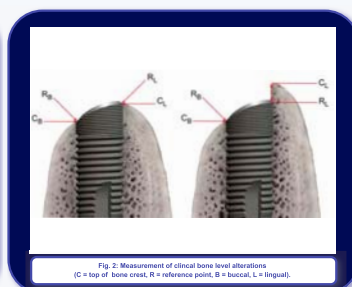

A total of 60 implants were placed in the study, and all implants were still in function after 16 weeks. The study population represented a wide variety of patients with respect to age (mean age 49 years; range 20-74 years), and smoking history (non-smokers 86%; smokers 14%). There was an equal distribution of men and women (30 men, 30 women). The mean edentulous period was 48 months (range 3-360 months). Seventy-three percent of the implants were placed in the mandible, and 27% in the maxilla. The most dominant position for implant placement was the mandibular first molar (55%).

The mean lingual marginal bone level alteration was -0.2 mm (range: -1.5 – 2.0), while the corresponding change on the buccal aspect was -0.4 mm (range: -12.5 – 2.0).

The complications reported in the study are limited to two loose healing abutments, and one patient presenting with a 12.5 mm loss of the buccal marginal bone level from implant placement to the 16 weeks re-entry visit.

Conclusions

The study results reveal maintained marginal bone levels at the buccal, and lingual/palatal aspect of OsseoSpeed™ Profile implants, and indicates that this implant is a predictable treatment option in cases where the alveolar crest anatomy is sloped in a lingual to buccal direction.



References

- Berglundh T, Abrahamsson I, Alboju JP, Lindhe J. Bone healing at implants with a fluoride-modified surface: an experimental study in dogs. Clin Oral Implants Res 2007; 18(2): 147-52
- Lee DW, Choi YS, Park KH, Kim CS, Moon IS. Effect of microthread on the maintenance of marginal bone level: a 3-year prospective study. Clin Oral Implants Res 2007; 18(4): 465-70

Contact

Dr. Robert Noelken, private practice for oral surgery, Paradiesplatz 7-13, D - 88 131 Lindau / Lake Constance, Germany, e-mail noelken@me.com